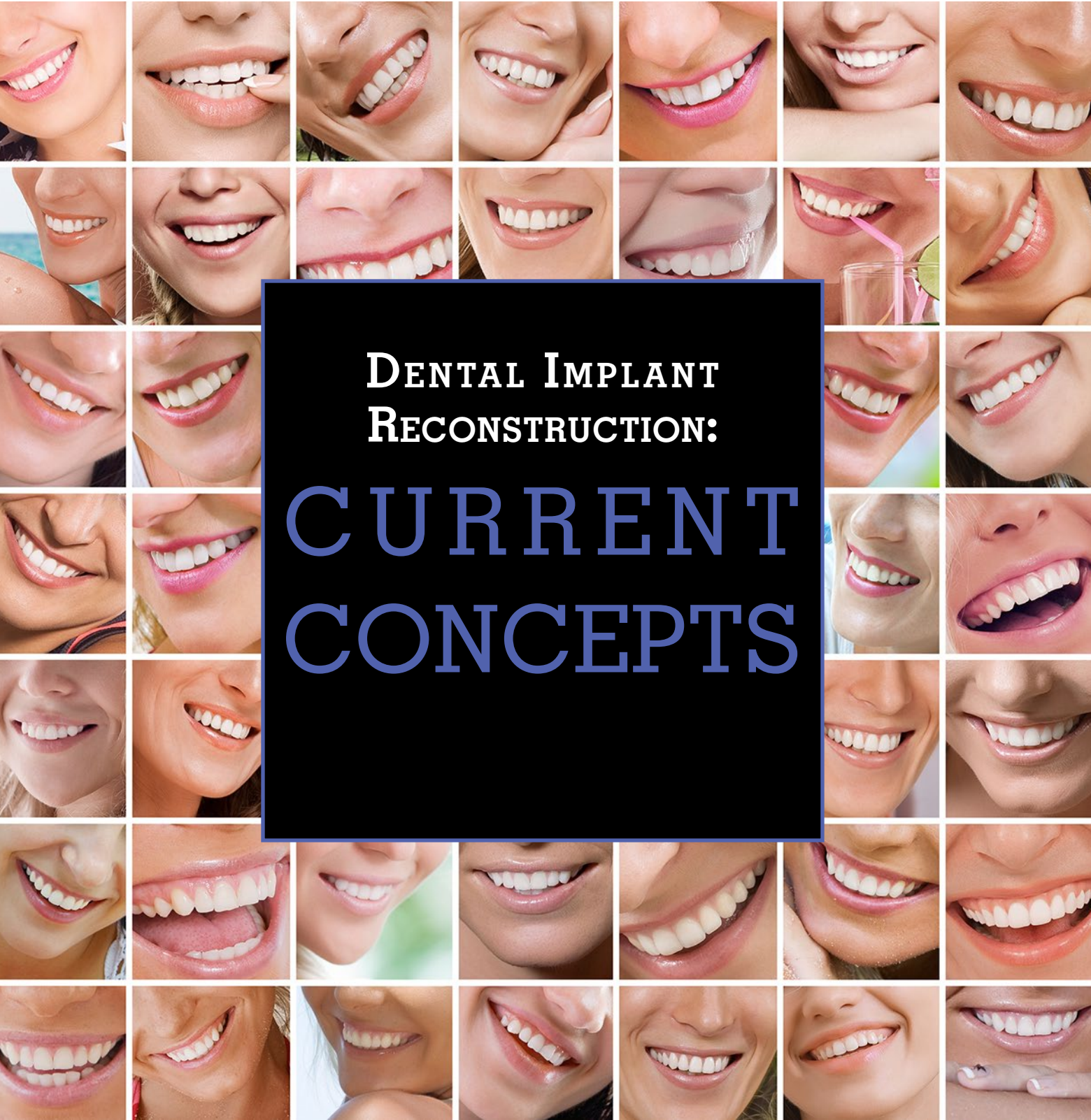




Alpha Omegan

Journal of the Alpha Omega International Dental Fraternity

Volume 108 • Number 4 | Winter 2015/16



DENTAL IMPLANT
RECONSTRUCTION:
CURRENT
CONCEPTS



Legal Implications of Implant Complications

By Richard J. Rymond, JD and Robert Kish, JD

Before joining Reminger in 1980 as a law clerk, Rick earned an economics degree and worked at a major accounting firm.

He leveraged his business experience in building a practice devoted to the defense of both medical and non-medical professionals. Rick has tried more than 100 first chair jury trials and has focused his practice on litigation involving: Medical and Dental Liability; Commercial Liability; Professional Liability; General Liability

In addition, Rick devotes substantial efforts to advising businesses and healthcare professionals on a wide variety of issues. He is a regular speaker not only at risk management programs for physicians, dentists and allied health professionals, but also at the Case School of Dental Medicine, where he serves as Assistant Professor.

Rick is a member of the Grace Hospital Board of Directors. Within the firm, Rick serves as the Co-Chair of the Dental Liability practice group. An officer of the corporation, he also is on Reminger's Executive, Management and Marketing Committees, and the Board of Directors. Rick played a significant role in establishing the Reminger Foundation, a 501(C)(3) charity which supports worthwhile causes in the communities where Reminger employees and clients live and work. He offers his ongoing guidance to the rotating Board of Directors of the Reminger Foundation charity.



While there are exceptions, as a general rule, malpractice claims arising out of implant dentistry arise when a patient experiences some sort of complication. To the extent that there are exceptions to this basic tenant, most, if not all, can be written off as anomalies.

This article provides the practitioner with an overview of the elements of a claim for malpractice, identifies frequent and common claims arising out of implant dentistry, and shares three case studies intended to demonstrate the most common claims and associated issues.

Basics of Malpractice Law

While there will be jurisdictional variations, as a general rule, in order for a patient to bring a successful claim for dental malpractice, he must establish the following elements through expert testimony:

1. Identification of the applicable standard of care;
2. Evidence of a deviation from the application standard of care;
3. A causal relationship between the alleged deviation from the applicable standard of care, and some physical injury or economic damage;
4. Evidence of the actual physical injury or damage sustained.

By way of an example, utilizing the relatively frequent claim involving an inferior alveolar nerve injury secondary to mandibular implant placement, the patient might allege the following:

- The standard of care requires the practitioner to obtain pre-treatment imaging in order to identify the amount of available bone in the mandibular arch in order to

eliminate or minimize the risk of IAN injury, and;

- The imaging obtained by the practitioner was inadequate for this purpose (note that, in this example, there is a wide range of opinion concerning what constitutes appropriate pre-treatment imaging, ranging from a belief that a simple periapical film is adequate, whereas others will opine that nothing short of CAT scan imaging will suffice), and;
- The failure to obtain adequate imaging resulted in a nerve injury, and;
- That the injury has resulted in altered sensation or loss of sensation impacting the patient in some specific way (i.e. biting of lip, complicated home prophylactic care, expenses associated with attempted repair or treatment of symptoms, etc.).

With very few exceptions, the courts will require the plaintiff to establish each of these elements through expert testimony. The law recognizes that a lay person would not be qualified to provide

competent testimony establishing the elements of a claim for malpractice.

On the other hand, evidence concerning the elements of such a claim will rarely hinge upon a universally recognized standard. Different experts may reasonably disagree as to what constitutes the standard of care (as suggested above), and will therefore disagree as to whether there has been any deviation. Moreover, experts may reasonably disagree as to both causation, and damages. Referencing the above example, the most comprehensive of imaging will not necessarily prevent a nerve injury; moreover, there may be disagreement among qualified experts as to whether a patient's subjective complaints can fairly be attributed to the alleged deviation or whether they are coincidental, or even fabricated.

While somewhat nuanced, in most jurisdictions, an identical standard of care applies to any practitioner performing implant dentistry. It is therefore not reasonable for a general dentist who places implants to respond to an allegation to the effect that the standard of care requires a certain type of imaging, to take the position that the type of imaging being suggested is a type only performed by oral and maxillofacial surgeons. On the other hand, it would be reasonable to take the position that there are various alternative reasonable imaging practices, provided that the practice adopted by the individual practitioner falls somewhere among those practices that would be considered acceptable by the implant community as a whole.

In most jurisdictions, the minimal qualifications of a standard of care expert are that the expert who is being offered has education and training similar to that of the defendant practitioner; courts may also require the proposed expert to spend a certain percentage of their professional time in teaching or clinical practice.

There are two common disputes that arise concerning the testimony by expert witnesses. First, experts will sometimes be challenged based upon their lack of expertise on the relevant topic. For instance, a general dentist who elects not to place implants in his or her own practice may not be permitted to offer opinions regarding the standard of care relative to another practitioner who has placed the implant(s) in question. Ultimately, the court will determine if the expert has the requisite expertise before permitting the testimony and the decision is often to allow the testimony and then leave it to the opposing attorney to attack the expert's credibility by highlighting their lack of experience. The jury

will then decide how much weight to give to the testimony of the expert.

Second, the reliability of the particular opinion offered by the expert may be challenged as not having an adequate scientific basis. This is not necessarily a challenge as to whether the expert's opinion is right or wrong; instead, the challenge is based on the lack of scientific support for the opinion or conclusion reached.

Once a patient is able to establish 1) the standard of care, 2) breach of the standard of care and 3) a causal relationship between the breach and some sort of physical injury or damages, the patient must establish their damages. In the context of dental malpractice claims (or any other personal injury action), damages may consist of economic and non-economic damages.

Economic damages generally include such items as medical and dental care expenses related to repairing or treating the complication experienced by the patient. This would not only include expenses incurred at the time of the litigation but also any future medical or dental care and treatment that will be required if established to the requisite probability by an expert. Another common category of economic damages includes lost wages, past or future, as well as diminished earning capacity. For example, a highly paid television news anchor who experiences an alteration to his or her speech because of a nerve injury may be able to claim that they will earn less in the future if their employment prospects are or become limited by the new speech issues. This would typically require additional experts to quantify the extent of the diminished earning capacity including a vocational expert and an economist. Of course, the more speculative the damages are perceived, the less likely they will be permitted by the court or accepted by a jury.


The mere fact that a patient experiences a complication arising out of implant dentistry will not establish a valid claim against the practitioner. Our system of justice acknowledges that complications can and do occur with reasonable care.

Frequency of Claims

It is impossible to identify every conceivable complication associated with implant dentistry which may produce a valid claim for malpractice. Moreover, there is no reliable statistical database concerning the frequency of particular types of claims.

That said, we believe that we can identify the most frequent claims. In general, the frequency with which we see particular types of claims

AUTHOR



Before joining Reminger Co., L.P.A., Robert served as a Special Agent of the Ohio Bureau of Workers Compensation, where he investigated allegations of fraud and abuse involving the state fund. Robert currently practices in Reminger's Columbus Office. He focuses his legal practice in the area of medical and dental negligence through the representation of physicians, hospitals, dentists and medical personnel in a variety of settings. Robert has also defended clients in cases involving premises liability, general liability and other areas of professional negligence

coincides with the frequency with which patients experience complications.

The most frequent and common claims arising out of implant dentistry are as follows:

- Injury to the inferior alveolar nerve;
- Implant failure; obviously, this can have multiple causes, including non-integration, non-restorability (due to angulation, for example), failure of remaining dentition intended to be incorporated into the overall treatment plan, etc.);
- Infection.

In our practice, we have seen a myriad of other complications giving rise to malpractice claims. We have defended claims involving sinus injury, damage to adjacent teeth, anesthesia complications, TMJ injuries, aspiration of implant components, etc. We have also defended matters involving claims to the effect that the implant dentist failed to adequately identify and address the underlying cause of edentulism (periodontal disease, a parafunctional habit and/or an underlying lesion).

Case Studies

Economic considerations will be a significant factor when a patient and his attorney decide whether to pursue a malpractice claim. Malpractice cases are expensive to litigate, and there must be sufficient damages to potentially lead to a significant settlement or verdict in order to offset the risk to the plaintiff attorney. Exemplar claims, which may give rise to litigation include the following:

I. Nerve Injuries

A. Background

Most nerve injury claims involve allegations to the effect that inadequate steps were taken

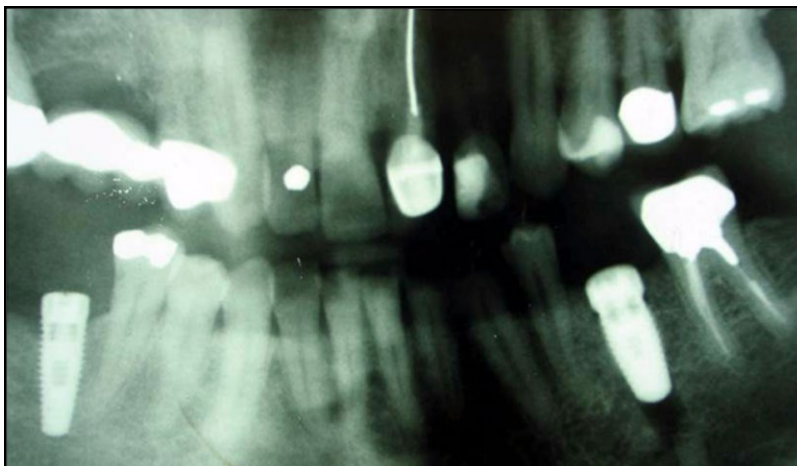


Image 1.1

to protect the integrity of the inferior alveolar nerve. Physiologically, these injuries may occur when the pilot drill is inserted to a depth above the superior aspect of the canal, or the implant itself impinges on the canal. Frequently, images obtained following implant placement suggest that the implant is superior to the canal, suggesting that the nerve injury may be attributable to inflammation near the apex of the implant. We have also seen a number of cases involving the placement of implants in close proximity to the mental foramen.

Allegations of negligence are varied and include the following:

- Inadequate pretreatment imaging in order to determine the amount of available bone.
- The placement of an implant beyond the amount of available bone as suggested by pretreatment imaging (note that some researchers recommend a “safety zone” of 1-2mm).
- Failure to abort a procedure when the patient experiences some sort of neurosensory reaction either in the preparation of the site, or at the time of implant placement.
- Failure to remove, or partially remove, the implant immediately following placement when the patient experiences neurosensory complaints.

There may also be allegations to the effect that the type of anesthesia selected for implant placement was improper; while many patients may prefer general anesthesia or block anesthesia, a number of practitioners advocate the use of infiltration anesthesia so that the practitioner can be alerted immediately in the event of an adverse neurosensory response.

As it relates to nerve injury cases, the “hot topic” is whether the standard of care requires CT imaging. Some practitioners believe that CT imaging is required by the standard of care in order to obtain the best possible information concerning the height, depth and quality of available bone. To be sure, whenever there is a nerve injury without the benefit of pretreatment CT imaging, we will be on the receiving end of a claim to the effect that the failure to obtain such imaging constitutes a deviation from the applicable standard of care.

B. Case Study

Image 1.1 depicts an implant in the lower left quadrant with a radiolucency apical to the apex of the implant.

Image 1.2 shows the implant site with greater clarity.

This patient presented to a very well-respected oral and maxillofacial surgeon with extensive experience in implant placement, with complaints of altered sensation in the lower left quadrant. Initially, it was unclear to the OMS whether the implant had perhaps been placed too deeply and then backed-out a few turns due to a concern about a possible IAN injury. Consideration was also given to the possibility that the pilot drill had caused injury to the IAN; however, it was noted that the width of the radiolucency apical to the implant did not appear to be suggestive of the use of a pilot drill. Upon closer inspection of the periapical film, Image 1.2, the OMS concluded that a fragment of bone had probably been pushed below the level of the apex of the implant and that this piece of bone had most likely caused some sort of direct or indirect trauma to the IAN. Interestingly, another periapical film taken several months later seemed to have confirmed this determination as the cylindrical piece of bone inferior to the radiolucency no longer appeared, suggesting that it had resorbed (Image 1.3).

A formal claim was never pursued, probably due to the fact that the OMS was not critical of the prior treating dentist, and, fortunately, the patient's symptoms of altered sensation ultimately resolved.

C. Defense

Had a claim been pursued, some additional information concerning the underlying treatment would have been required. In this instance, it is unknown whether there was ever any attempt to back-out the implant a few turns after placement and/or when the patient's complaints of altered sensation initially arose. In any event, as counsel for the initial treating dentist, we would point out that both the implant itself, and the radiolucency apical to the implant, appear to be superior to the nerve canal. Unfortunately, IAN injuries can occur under the very best of care with implant placement.

We would also want to know if there was ever any sort of recommendation to remove the implant. We know from the OMS who treated this complication that the patient was given the option of having the implant removed, and declined that offer.

D. Outcome

As indicated above, there was no claim or lawsuit brought against the dentist who placed the implant depicted on Images 1.1, 1.2 and 1.3.

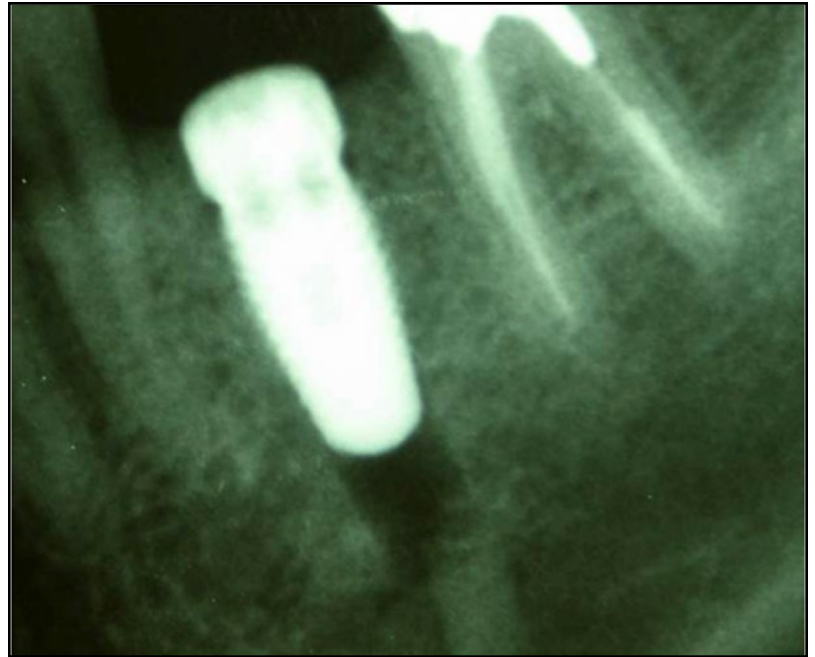


Image 1.2

E. Lessons Learned

A large percentage of IAN injuries associated with implant placement resolve spontaneously. In this instance, it is fortunate that neither the original treating dentist, nor the OMS overreacted. Had that implant been removed, and had efforts been made to retrieve the fragment of separated bone which most likely caused this temporary injury, the patient may well have been left with a permanent injury.

As in any IAN injury case, the treating dentist is likely to be closely scrutinized relative to pretreatment planning. Certainly, there would have been questions about what images were taken, what those images

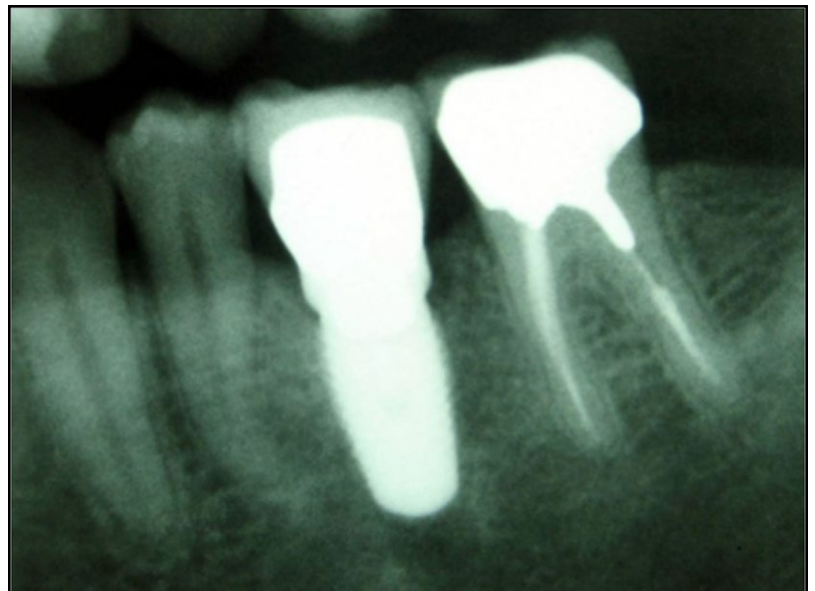


Image 1.3

showed, and whether pre-treatment CT images were obtained. Depending upon what information was available from the pretreatment imaging, there would have been additional questions as to whether the length of the implant selected was appropriate.

As it relates to the OMS, he wisely documented his offer to remove the implant, and explained to the patient the pros and cons of this treatment option. He further documented that the patient made an informed decision to refuse the removal of the implant.

II. Non-restorable Implant

A. Background

We frequently see claims to the effect that the practitioner has placed implants which are non-restorable. In most such instances, the position or angulation of the implant is such that it is impossible to restore the implant while maintaining the integrity of the dental arch. In these instances, the most frequently asked questions are as follows:

- Did the practitioner avail himself of the technology available through a 3-D CT scan?
- Was there a diagnostic wax up of the case?
- Was a surgical guide utilized?

Additionally, in our experience, many of these claims arise where a restorative dentist has referred the patient to a specialist for the placement of implants, and the patient is returned to the restorative

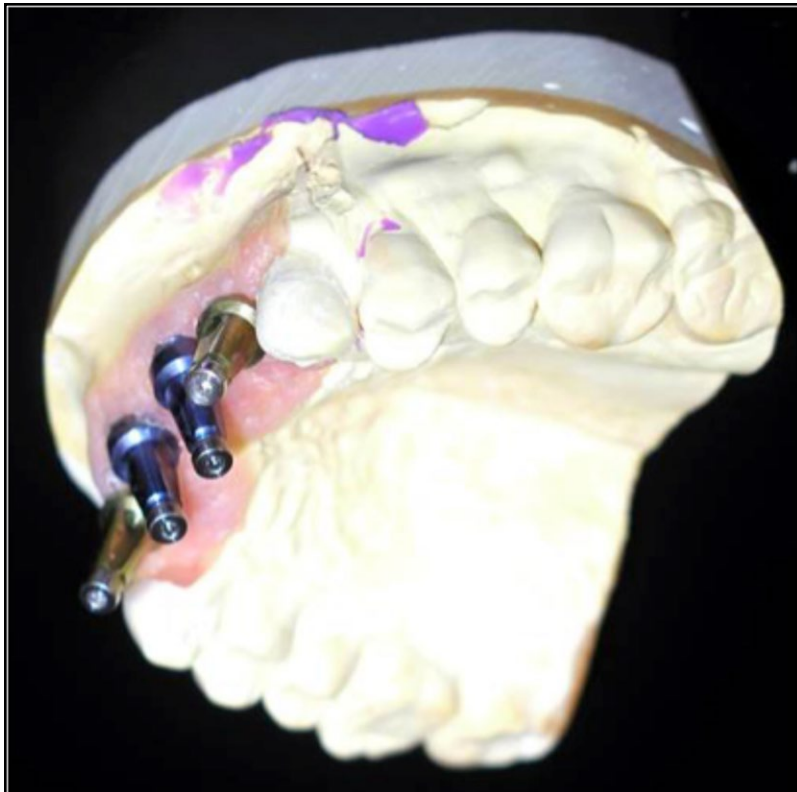


Image 2.1

dentist by the specialist with the implants in place. This frequently gives rise to a claim to the effect that there was inadequate coordination in the treatment planning phase between the restorative dentist and the implant dentist.

B. Subject Claim

Images 2.1 and 2.2 depict the angulation of four implants in the upper anterior, designed to replace missing teeth numbers 7, 8, 9 and 10. As is evident from the angulation of the implants, a significant challenge was created for the restorative dentist.

In this instance, the plaintiff alleged inadequate treatment planning, and specifically cited the absence of a diagnostic wax up, surgical guide, or 3-D CT imaging. Plaintiff's expert witness opined that any one of these three planning tools would have eliminated the risk of this particular outcome.

C. Defenses

Unfortunately, a picture is worth a thousand words. There is no question but that the subject implants are far from parallel. In this particular matter, the defense took the position that the implants were within the range of acceptable and argued that either angled abutments or custom abutments could be utilized in order to achieve a favorable functional result. In fact, custom abutments were fitted on this case, and the patient was able to achieve adequate function. However, the aesthetic result was far from ideal.

D. Outcome

This claim was settled early in the litigation process.

E. Lessons Learned

There must be good coordination between the restorative dentist and the implant dentist. Moreover, effective treatment planning arguably requires the implant dentist to avail himself of at least one of the various tools available in order to achieve an acceptable or optimal outcome. In fact, in this case, had a diagnostic wax up been performed, or if a surgical guide was utilized, or if additional imaging was obtained prior to implant placement, the likelihood of this particular outcome would have been significantly reduced.

Even where an implant is successfully placed without any immediate apparent complication, the angle at which the implant was placed can lead to litigation when the patient is unable to be restored in an aesthetically satisfactory manner. In this instance, the patient pursued a claim for additional expenses associated with implant removal and replacement, aggravation, pain and discomfort associated with implant removal and replacement, and the delay in terms of achieving a final prosthesis.

III. Infection

A. Background

A common complication often seen in implant malpractice cases involves the development of infection either locally or, in more significant cases, extending into the surrounding bone as osteomyelitis. Local infections that are treated promptly and correctly often resolve quickly and require little more than a short course of antibiotics. In some instances, resolution is achieved with new bone grafting and a new implant after the infection is cleared.

Litigation arising out of infection associated with implant dentistry is not uncommon. That said, the fact patterns giving rise to these claims vary widely. In our practice, we have seen claims which include the following:

- Failure to adequately address existing infection before placing implants.
- Failure to timely diagnose and offer definitive treatment options following implant placement.
- Improper management of infection including failure to prescribe appropriate antibiotics leading to spread of the infection.
- Attempting to treat chronic infection for prolonged periods of time without obtaining an infectious disease consult or cultures of the offending organism.
- Delay in diagnosis of infection leading to damage to surrounding structures (supportive bone and sinus) and adjacent teeth.
- Secondary complications associated with prolonged antibiotic therapy.
- Spread of infection to other organs including the lungs, heart and brain.

B. Subject Claim

The patient depicted in illustration 3.1 presented to an OMS having undergone a grafting procedure at the site of tooth number 29. The patient was in pain, and presented with exudate at the grafting site. Clinically, and based upon the radiographic findings, the OMS diagnosed the patient with localized infection at the graft site. He debrided the area, and removed the prior grafting material. After a modest course of antibiotics, the infection was cleared, and a second graft was placed. See illustration 3.2. After several weeks of active treatment, including two surgical procedures, and several months following the second grafting procedure, the area could be restored. See illustrations 3.3 and 3.4. Ultimately, the patient achieved a good result.

The patient pursued a claim against the dentist who performed the initial grafting procedure alleging substandard care associated with the

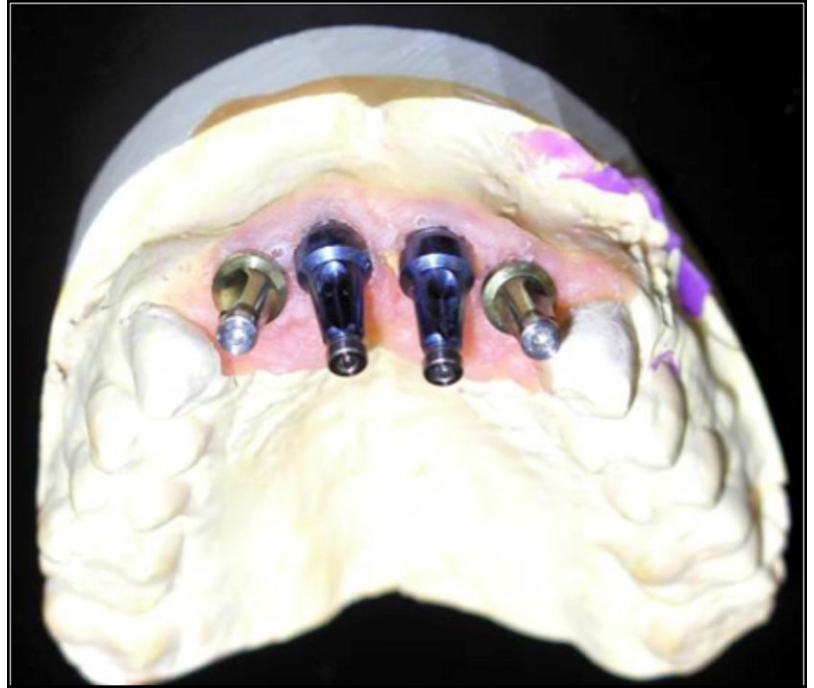

Image 2.2

technique, the choice of grafting material, and the failure to timely address infection.

C. Defense

Generally, it was the position of the initial treating dentist that the grafting material utilized at the time of the first procedure was

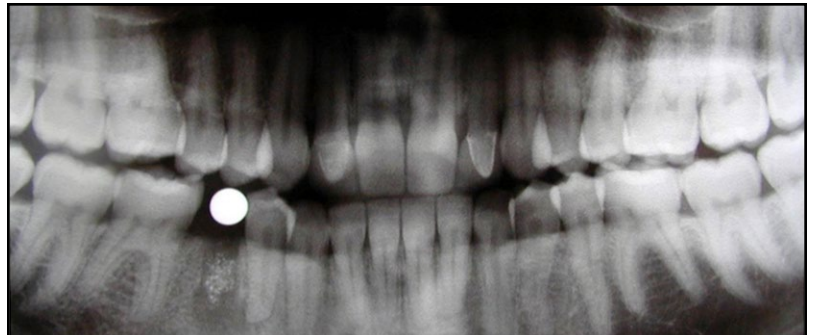


Image 3.1

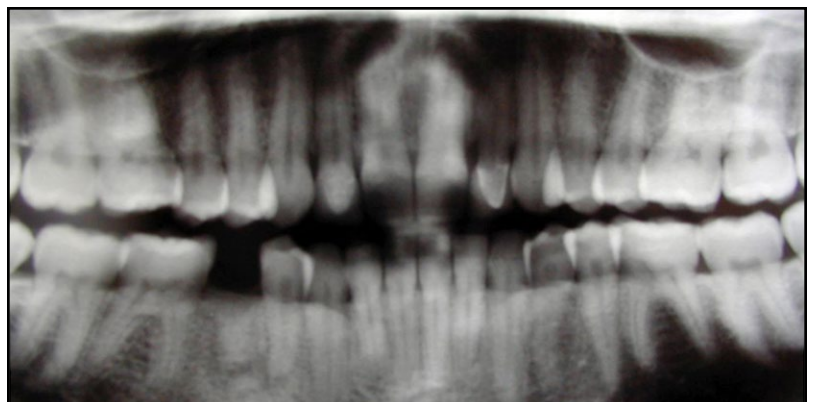


Image 3.2

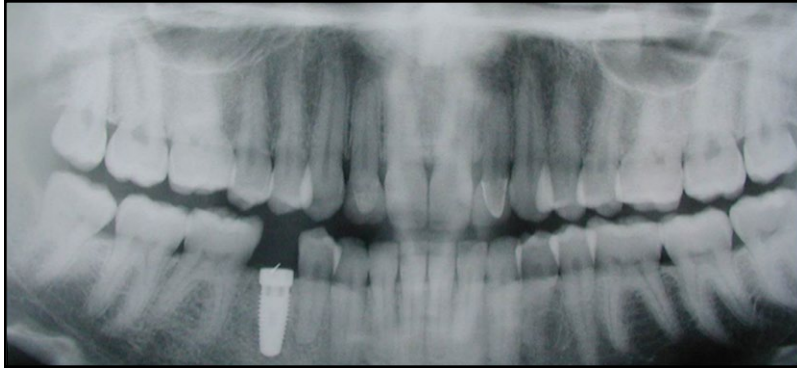


Image 3.3

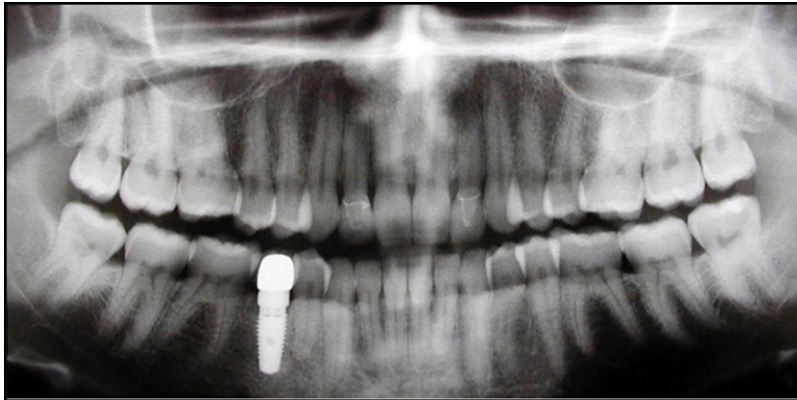

Image 3.4

acceptable, as was the technique. Unfortunately, under the very best of care, patients may experience infection.

D. Outcome

We understand that this matter was resolved in the claim stage for a nominal sum. The decision to settle the claim was triggered by a determination that the grafting material utilized at the time of the initial procedure was suboptimal, at best. Moreover, it was believed that there would be challenges associated with the initial delay in diagnosing and offering definitive treatment for the area of infection surrounding the grafting material.

E. Lessons Learned

As with all stages of implant dentistry, from treatment planning, to grafting, to implant placement and ultimately restoration of the implant, it is essential that the treating dentist be up-to-date on current techniques. In this instance, the damages experienced by the patient were nominal. Had the original dentist attempted to place an implant at the graft site without adequately addressing infection, the outcome could have been far worse. In fact, we have seen instances where localized infection has eroded through the mandible necessitating extensive reconstruction.

While not illustrated by this case study, as a matter of risk management advice, we would suggest that the practitioner error in favor of involving other specialists in managing infection where immediate measures do not succeed.

Risk Management

Informed Consent

In general, no practitioner may provide care to a patient without obtaining the patient's Informed Consent. Informed Consent requires the practitioner to communicate to the patient the risks, benefits, and alternatives to the proposed care. The risks which must be communicated are those which are most frequent, and the most serious. The benefits which must be communicated are those associated with the expected outcome and limitations associated with the expected outcome. The alternatives which must be communicated include all reasonable alternatives. Without this information, the patient cannot make an informed decision.

In most jurisdictions, the law does not require the Informed Consent process to be in writing. However, there are practitioners who will opine that there is a standard of care which requires the informed consent process to be in writing, and there are some courts which will permit a jury to decide whether the standard of care requires the process to be in writing. By virtue of the foregoing, and since a written document is the best evidence that the patient gave informed consent, it is our recommendation that informed consent for implant dentistry always be in writing. Furthermore, we believe that the method by which the written informed consent is documented is important. Pre-printed forms are fine provided that they identify the risks specific to the procedure that is being proposed. While this may seem obvious, we have seen generic forms that dentists use that either do not adequately identify the unique risks faced by the patient or they simply list generic risks applicable to virtually any procedure, i.e. pain or bleeding.

Poor informed consent procedures may trigger litigation that otherwise would not be pursued. Patients who understand the risks of a procedure prior to treatment are much more accepting of the complication when it occurs. On the flip side, patients who experience a complication that was not discussed with them before treatment are more likely to conclude that the complication should not have occurred and must have been the result of substandard care.

It should be noted that, in most jurisdictions, in order for a patient to prevail on a claim

premised upon a lack of informed consent, the patient must demonstrate that, if they had been given all of the relevant information, they would have elected to forego the proposed treatment, and that a reasonable person in their shoes would have also declined treatment. The patient must further demonstrate that they experienced a non-disclosed complication.

Treatment Plans

From a risk management perspective, treatment plans should be in writing with a copy given to the patient prior to the start of treatment. The treatment plan should contain terms and descriptions, to the extent possible, that are able to be understood by a lay person without dental training. The costs of the proposed treatment should ideally be set out and preferably broken down by line item or at least by stage of treatment, i.e. the fees for extraction, implant and restoration. We have seen cases where patients have claimed that the treatment they received was not what they expected and many of these claims could either have been avoided or minimized with better documentation of the treatment plan and better documentation of the dentist's communications with the patient.

Records

Where appropriate, we would suggest that records include the following:

- Documentation of the patient's chief complaint;
- Documentation concerning the patient's dental and medical history;
- Documentation concerning the clinical findings of the dentist before a treatment plan is presented;
- Documentation of any objective findings arising out of testing such as lab work;
- Documentation concerning radiologic findings;
- Documentation concerning recommendations given to the patient;
- Documentation concerning specific alternatives given to the patient;
- Documentation concerning any referrals made;
- Documentation concerning any communications with other involved healthcare providers; this is extremely important in situations where the implants are going to be placed by one practitioner, and restored by another;
- Documentation concerning the outcome including any complications;

- Documentation concerning communications with the patient concerning any unfavorable outcome or complication;
- Documentation concerning non-compliance.

Documentation can be critical to the defense of an implant case and, fortunately or unfortunately, can even be as outcome determinative as the actual care provided by the practitioner. Testimony by the patient and dentist will be evaluated for credibility by the jury but documentation is often accepted at face value. The good news is that documentation is completely within the control of the dentist and this presents the dentist with the opportunity to accurately record what actually transpired. In fact, strong documentation may deter a patient (or potential attorney) from filing a lawsuit if it appears there will be no significant question as to what was said, what was done, and what resulted from the treatment.

In addition to the foregoing, from a risk management standpoint, we would be remiss if we did not reinforce the advice that records should never be altered. While there will be legitimate reasons to make addendums to progress notes and/or perhaps even redact a progress note (such as where it has been entered into the wrong chart) this should always be done with complete transparency.

Treating Complications

Every dentist who places implants will have patients who experience complications. It is often how the practitioner handles the complication that determines whether they will be subject to a malpractice claim.

Although it should go without saying, the practitioner must convey an appreciation of the complication the patient experienced with compassion and understanding. Dentists who are perceived as dismissive, condescending or unsympathetic are far more likely to have patients who seek legal counsel.

Many malpractice claims have originated with comments made by subsequent treating dentist, which are critical of the first dentist without knowing all of the facts. Where possible and within the dentist's skill and comfort level, the original dentist should attempt to address any complications that arise from their treatment. Of course, if the complication requires referral to a specialist, the patient must be referred to an appropriate specialist in a timely manner. Failure to make a timely referral can serve to make a bad situation worse. **AO**